REVIEW

The 2022 WHO classification of thyroid tumors: novel concepts in nomenclature and grading

C Christofer Juhlin[1,2], **Ozgur Mete**[3,4,5] and **Zubair W Baloch**[6]

[1]Department of Oncology-Pathology, Karolinska Institutet, Stockholm, Sweden
[2]Department of Pathology and Cancer Diagnostics, Karolinska University Hospital, Stockholm, Sweden
[3]Department of Pathology, University Health Network, Toronto, ON, Canada
[4]Endocrine Oncology Site, Princess Margaret Cancer Centre, Toronto, ON, Canada
[5]Department of Laboratory Medicine and Pathobiology, University of Toronto, Toronto, ON, Canada
[6]Department of Pathology & Laboratory Medicine, Perelman School of Medicine, University of Pennsylvania, Philadelphia, PA, USA

Correspondence should be addressed to Z W Baloch: baloch@pennmedicine.upenn.edu

Abstract

The fifth edition of the Classification of Endocrine and Neuroendocrine Tumors has been released by the World Health Organization. This timely publication integrates several changes to the nomenclature of non-neoplastic and neoplastic thyroid diseases, as well as novel concepts that are essential for patient management. The heterogeneous group of non-neoplastic and benign neoplastic lesions are now collectively termed as 'thyroid follicular nodular disease' to better reflect the clonal and non-clonal proliferations that clinically present as multinodular goiter. Thyroid neoplasms originating from follicular cells are distinctly divided into benign, low-risk and malignant neoplasms. The new classification scheme stresses that papillary thyroid carcinoma (PTC) should be subtyped based on histomorphologic features irrespective of tumor size to avoid treating all sub-centimeter/small lesions as low-risk disease. Formerly known as the cribriform-morular variant of PTC is redefined as cribriform-morular thyroid carcinoma since this tumor is now considered a distinct malignant thyroid neoplasm of uncertain histogenesis. The 'differentiated high-grade thyroid carcinoma' is a new diagnostic category including PTCs, follicular thyroid carcinomas and oncocytic carcinomas with high-grade features associated with poorer prognosis similar to the traditionally defined poorly differentiated thyroid carcinoma as per Turin criteria. In addition, squamous cell carcinoma of the thyroid is now considered a morphologic pattern/subtype of anaplastic thyroid carcinoma. In this review, we will highlight the key changes in the newly devised fifth edition of the WHO classification scheme of thyroid tumors with reflections on its applicability in patient management and future directions in this field.

Key Words

- WHO classification
- thyroid tumor
- thyroid carcinoma
- grading
- nomenclature

Endocrine-Related Cancer (2022) **30**, **e220293**

Introduction

The fifth edition of the World Health Organization (WHO) Classification of Endocrine and Neuroendocrine Tumors is a timely publication that easily lends itself to the years of experience in the field of diagnostic and molecular thyroid pathology. It contains appropriate changes to nomenclature, grading and prognostication of thyroid proliferations based on pathologic features and molecular profile. Therefore, it is important that endocrinologists and practicing physicians who manage thyroid nodules acquaint themselves with this new

https://erc.bioscientifica.com
https://doi.org/10.1530/ERC-22-0293
© 2022 the author(s)
Published by Bioscientifica Ltd.
Printed in Great Britain

Downloaded from Bioscientifica.com at 03/10/2026 12:42:14AM
via free access

classification scheme (Baloch *et al.* 2022) (Fig. 1). Several tumor entities have been renamed to stay congruent with underlying tumor biology and/or histogenesis as well as molecular profiles. The role of diagnostic and predictive biomarkers is coupled with morphological parameters and tumor proliferation to enable dynamic clinical risk stratification and prognosis.

In this brief review, important changes and updates are highlighted in order to orientate the reader further.

Benign follicular cell-derived thyroid tumors

Clinically, the term 'goiter' relates to an enlarged thyroid gland, a finding that is associated with various neoplastic and non-neoplastic disorders. Goiter often presents as a nodular and rarely as a diffuse process. Most agree that the terms 'colloid nodules,' 'multinodular goiter,' 'adenomatous goiter' and 'multinodular hyperplasia' often used by pathologists are not reflective of the underlying pathology besides the mere confirmation of clinical findings. Molecular analyses of individual nodules in such cases have revealed that a good proportion of goitrous nodules is monoclonal and represents neoplastic proliferations making it impossible to distinguish between non-neoplastic and benign neoplastic follicular neoplasms i.e. adenomas on the basis of morphology alone (Mete & Asa 2012). In addition, most of the adenomatous nodules encountered in patients with DICER1, PTEN and PTEN-like syndromes (Harrer *et al.* 1998*a*,*b*, Derwahl & Studer 2002) also represent multiple follicular adenomas (Wasserman *et al.* 2018, Cameselle-Teijeiro *et al.* 2021). Therefore, an umbrella term of 'follicular nodular disease' (FND) has been proposed in the latest WHO classification, to avoid the above-mentioned issues (Baloch *et al.* 2022).

In the 2017 WHO classification scheme of thyroid neoplasms, follicular adenoma was the only entity included in the benign follicular cell-derived tumors; however, in the fifth edition, 'follicular adenoma with papillary architecture' (previously termed as papillary adenomatous/hyperplastic nodule) is also included in

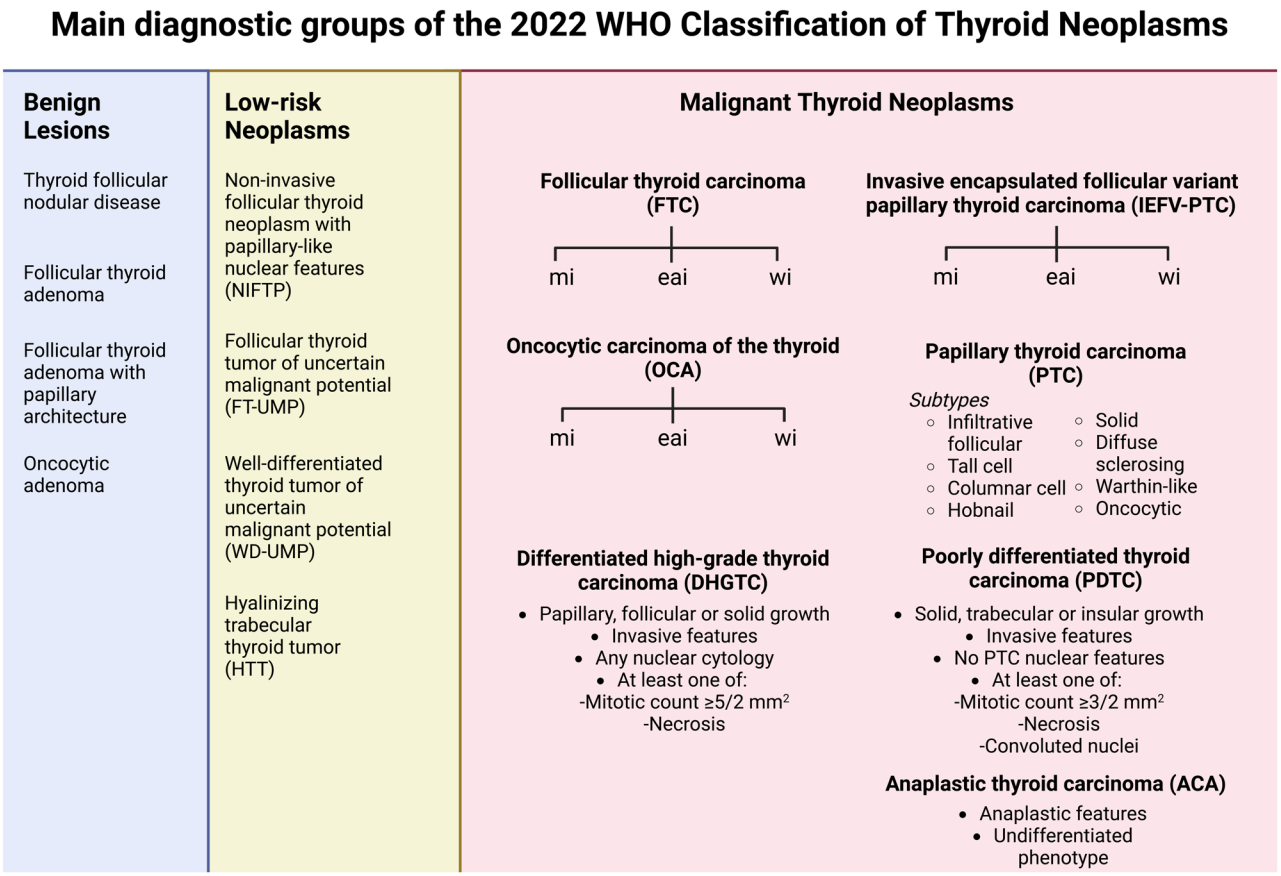

Figure 1
Overview of the main diagnostic groups of the 2022 WHO classification of thyroid tumors. Not included here are mixed medullary and follicular cell-derived carcinomas, salivary gland-type carcinomas of the thyroid, thyroid tumors of uncertain histogenesis, intrathyroid thymic tumors and embryonal thyroid neoplasms. MI, minimally invasive; EAI, encapsulated angioinvasive; WI, widely invasive. Created using BioRender.com.

https://erc.bioscientifica.com
https://doi.org/10.1530/ERC-22-0293
© 2022 the author(s)
Published by Bioscientifica Ltd.
Printed in Great Britain

Downloaded from Bioscientifica.com at 03/10/2026 12:42:14AM
via free access

the benign neoplasm category. Follicular adenoma with papillary architecture is a well-demarcated and non-invasive, often encapsulated tumor with intra-follicular centripetal papillary growth, and the lesional cells lack nuclear features of papillary thyroid carcinoma (PTC) (Mete & Asa 2012, Baloch *et al.* 2022). These tumors are often associated with autonomous hyperfunction and may therefore appear as hot or warm nodules on radionuclide thyroid scan (Mete & Asa 2012). Molecular analyses have shown that these are driven by *TSHR*, *GNAS* or *EZH1* mutations and alterations that activate the protein kinase A (PKA) pathway (Parma *et al.* 1993, Gozu *et al.* 2010). These tumors may also occur in the setting of McCune–Albright and Carney complex syndromes; both are PKA pathway-related conditions driven by *GNAS* and *PRKAR1A* mutations, respectively (Kamilaris *et al.* 2019, Nosé *et al.* 2022). Moreover, non-functional follicular adenomas with papillary architecture can harbor *DICER1* mutations, and a subset of these have been reported in association with DICER1 syndrome (Wasserman *et al.* 2018, Cameselle-Teijeiro *et al.* 2021, Juhlin *et al.* 2021). Thus, the association between thyroid function and related tumor syndromes makes the distinction between these tumors clinically significant. Furthermore, a diagnosis of oncocytic follicular adenoma requires >75% of tumor cells to exhibit oncocytic features (Baloch *et al.* 2022). Overall, oncocytic thyroid tumors represent a distinct entity of thyroid neoplasms, supported by specific genetic aberrations including mitochondrial DNA mutations and increased copy number alterations (Gopal *et al.* 2018, Doerfler *et al.* 2021, McFadden & Sadow 2021).

Low-risk follicular cell-derived thyroid neoplasms

The naming of a group of thyroid neoplasms as 'low risk' was introduced in the fourth edition of the WHO classification of thyroid tumors. This was groundbreaking as it really identified a group of tumors based on their pathologic features (most with interobserver variability) and molecular profiles which was completely aligned with the clinical behavior. However, the new WHO classification has revolutionized this concept by integrating this term into the classification framework and also by expanding its spectrum to include: non-invasive follicular thyroid neoplasm with papillary-like nuclear features (NIFTP), thyroid tumors of uncertain malignant potential (consisting of follicular thyroid tumors of uncertain malignant potential (FT-UMPs) and well-differentiated tumors of uncertain malignant potential (WD-UMPs)) and hyalinizing trabecular tumors (HTTs) (Baloch *et al.* 2022). Collectively, when rendered in light of strict diagnostic criteria, these entities clinically behave in more or less benign fashion and do not require aggressive treatment modalities. Except for HTT, these neoplasms are mostly *RAS*-driven, and detection of any non-RAS-like molecular signature (e.g., BRAF p.V600E) or high-risk molecular alterations (e.g., *TERT* promoter mutations) prompts re-evaluation of pathologic features to exclude overt malignancy.

NIFTP is a well-demarcated or encapsulated and non-invasive neoplasm, completely follicular-patterned with PTC-related nuclear atypia lacking high-grade features (mitoses/necrosis) (Hodak *et al.* 2016, Thompson 2016). Most NIFTPs are *RAS*-driven or exhibit codon 601 *BRAF* mutations, and presence of *BRAF* p. V600E mutation is an exclusion criterion for NIFTP in the new WHO classification of thyroid neoplasms. A subset of NIFTP may harbor gene fusions (*THADA* gene fusions or *PAX8::PPARG*) (Baloch *et al.* 2022). In the fifth edition of WHO classification, the diagnostic term NIFTP can be applied to sub-centimeter lesions (in the absence of the *BRAF* p.V600E mutation, excluding lesions measuring less than 0.3 cm) and oncocytic lesions (with >75% oncocytic cells) fulfilling the strict diagnostic criteria (Baloch *et al.* 2022).

Thyroid tumors of uncertain malignant potential are rare lesions in which histological confirmation of capsular and/or vascular invasion is equivocal. These tumor entities require extensive microscopic assessment of the entire capsule/tumor interface, as a single focus of invasive focus would disqualify these diagnoses.

HTTs are follicular cell-derived thyroid neoplasms with PTC-related nuclear atypia, trabecular growth pattern, extracellular hyaline matrix and specific *PAX8::GLIS1* and *PAX8::GLIS3* fusions (Nikiforova *et al.* 2019). Metastases associated with HTT have only been reported in single, historic cases and never in an HTT with a verified *GLIS* fusion (Baloch *et al.* 2022). While molecular testing will confirm the diagnosis, the entity is well-known to exhibit membranous Ki67 immunoreactivity if stained using the MIB1 clone at room temperature (Leonardo *et al.* 2007).

Follicular thyroid carcinoma and follicular variant of papillary thyroid carcinoma

Follicular thyroid carcinomas are mostly *RAS*-driven, invasive tumors lacking nuclear cytology of PTC.

https://erc.bioscientifica.com
https://doi.org/10.1530/ERC-22-0293
© 2022 the author(s)
Published by Bioscientifica Ltd.
Printed in Great Britain

Downloaded from Bioscientifica.com at 03/10/2026 12:42:14AM
via free access

In the 2017 WHO classification, FTC was subdivided into three different subtypes to reflect the overall prognosis based on tumor capsule invasion and foci of vascular invasion: minimally invasive FTC, encapsulated angioinvasive FTC and widely invasive FTC. This histological stratification is retained in the 2022 WHO classification, as the extent of the invasive features correlates to patient survival (Baloch *et al.* 2022). The related *RAS*-driven entity follicular variant of PTC (FVPTC) is similar to FTC in terms of predominant growth patterns but exhibits subtler nuclear features of most PTCs that are linked to *BRAF* p.V600E-like molecular alterations.

FVPTCs are now subdivided into infiltrative and encapsulated subtypes. *Infiltrative FVPTCs* are *BRAF*-driven tumors with florid nuclear atypia with invasion of the surrounding thyroid parenchyma and lymphatic vessels (thus behaving as bona fide PTCs). This diagnostic category has been challenged by some experts who believe that these tumors represent infiltrative classic PTC with predominant follicular growth. *Encapsulated FVPTCs* are *RAS*-driven lesions with a similar invasive pattern as FTCs (capsular and/or proclivity to vascular invasion rather than lymphatics) (Baloch *et al.* 2022). Similar to FTC, FVPTCs also exhibit a correlation between the extent of invasion and patient prognosis (Xu *et al.* 2015). To better reflect this, the 2022 WHO classification therefore subdivides FVPTCs as either minimally invasive, encapsulated angioinvasive or widely invasive.

Papillary thyroid carcinoma: a better mix of old and new

In the fifth edition of the WHO classification, much focus is placed on histological subtyping of PTC (Baloch *et al.* 2022); reasons being the correlation between *BRAF*-driven PTC and worse patient outcomes compared to *RAS*-driven PTC and the overrepresentation of *BRAF* p.V600E driver mutations in specific PTC subtypes (previously designated as 'variants') (Kebebew *et al.* 2007, Baloch *et al.* 2022). Oncogenic *BRAF* mutations are present in 50–60% of all PTCs but are specifically overrepresented in the tall cell, columnar cell and hobnail subtypes – the PTCs with the higher risk of lymph node metastasis, loco-regional recurrences, distant metastases and poor outcomes (Baloch *et al.* 2022). Hence, sub-centimeter PTCs should also be histologically subtyped, as small subsets of these lesions have been reported to follow an aggressive clinical course similar to their large-sized counterparts. It is no longer recommended to simply refer to PTCs measuring less than or equal to 1.0 cm as 'papillary thyroid microcarcinoma' without any additional subtype information. A number of histological subtypes are now listed apart from classic PTC, the most common being the infiltrative follicular variant, tall cell, columnar cell, hobnail, solid, diffuse sclerosing, Warthin-like and oncocytic PTC (Fig. 2). The 2022 WHO classification lists these subtypes in terms of histological definitions and molecular profiles (Baloch *et al.* 2022). Like other forms of differentiated thyroid carcinomas, the new classification requires exclusion of PTCs with high-grade features (tumor necrosis and/or ≥5 mitoses per 2 mm^2) to a new diagnostic category (see below).

The term Hürthle: the end of a famous misnomer

In the former fourth edition of the WHO guidelines, oncocytic thyroid carcinoma was listed as a separate entity, apart from follicular thyroid carcinoma (FTC) due to its unique histology, molecular profile and patient prognosis. In the fifth edition, this distinction is retained, but the nomenclature 'Hürthle' is discouraged, as it derives from Karl Hürthle, a German histologist who actually described parafollicular C cells in the canine thyroid gland rather than oncocytic cells of the thyroid (Caturegli & Ruggere 2005). In the fifth edition of the WHO guidelines, oncocytic carcinoma of the thyroid (OCA) requires histological evidence of malignancy (capsular and/or vascular invasion) and absence of high-grade features (tumor necrosis and/or ≥5 mitoses per 2 mm^2) and pathologic stratification into minimally invasive, encapsulated angioinvasive and widely invasive subtypes is recommended similar to FTC (Baloch *et al.* 2022). Similar to high-grade features, morphologic dedifferentiation should also be recognized given the poor prognosis associated with oncocytic poorly differentiated thyroid carcinoma (Lukovic *et al.* 2021).

High-grade follicular cell-derived carcinomas: morphologic validation of clinical outcomes

It is well-known that a subset of differentiated thyroid carcinomas (PTCs, FTCs) exhibiting high-grade pathologic features such as increased mitotic index and the presence of tumor necrosis are associated with aggressive clinical course similar to tumors classified as poorly differentiated thyroid carcinoma (PDTC) (Hiltzik *et al.* 2006, Gnemmi *et al.* 2014). The diagnosis of PDTC is made based on the so-called Turin criteria; (1) presence of a solid/trabecular/

https://erc.bioscientifica.com
https://doi.org/10.1530/ERC-22-0293
© 2022 the author(s)
Published by Bioscientifica Ltd.
Printed in Great Britain

Downloaded from Bioscientifica.com at 03/10/2026 12:42:14AM
via free access

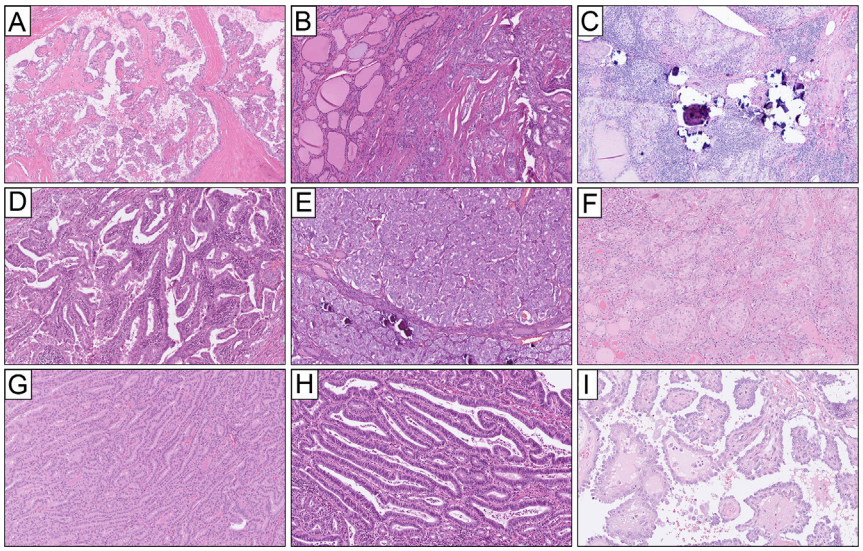

Figure 2
Histological hallmarks of the most commonly encountered papillary thyroid carcinoma subtypes. New to the 2022 WHO classification is the recommendation to subtype all papillary thyroid carcinoma (PTC) specimen irrespective of tumor size, as some subtypes are coupled to worse patient outcome and therefore of potential value to identify on the histological level. (A) Classic PTC with a papillary growth and florid nuclear atypia. (B) infiltrative follicular variant PTC growing into the surrounding thyroid parenchyma. (C) Diffuse sclerosing subtype represented by tumor cells in solid formations, sometimes with squamous metaplasia, against a dense fibrotic stroma with multiple psammoma bodies and associated chronic inflammation. (D) Warthin-like PTC built up by oncocytic tumor cells lining papillary cores with lymphoplasmacytic cells. (E) Solid PTC defined by ≥50% of solid or trabecular growth. (F) PTCs with ≥75% oncocytic cells are defined as oncocytic PTC. (G) Tall-cell PTC with its characteristic 'tram track' appearance on low power and eosinophilic tumor cells with a height of at least three times the width. (H) Columnar cell subtype of PTC with columnar cells with pseudostratification arranged in papillary and pseudoglandular formations. This subtype is characterized by CDX2 immunoreactivity in approximately 50% of tumors. (I) Hobnail PTC defined as ≥30% of the tumor cells exhibiting hobnail features, such as micropapillary growth apical snouts and cell budding. The bottom row (G-I) represents the PTC subtypes associated with worse patient outcomes compared to other subtypes.

insular growth pattern, (2) absence of the conventional nuclear features of papillary carcinoma and (3) presence of at least one of the following: convoluted nuclei; >3 mitoses per 2 mm^2 (10 high-power fields) and tumor necrosis (Volante *et al.* 2007). However, some experts have considered a mitotic index ≥5 mitoses per 2 mm^2 (10 high-power fields) and/or tumor necrosis as indications of a poorly differentiated phenotype even in the absence of morphologic dedifferentiation (Hiltzik *et al.* 2006). In the fifth edition of the WHO classification, an intermediate entity of 'differentiated high-grade thyroid carcinoma' (DHGTC) is therefore introduced for PTCs and FTCs/OTCs with ≥5 mitoses per 2 mm^2 and/or tumor necrosis to highlight high-risk differentiated thyroid carcinomas (Baloch *et al.* 2022). The tumors classified as such may have retained PTC-related nuclear atypia or a follicular growth pattern and features that are not acceptable for a PDTC diagnosis (Fig. 3). From a molecular standpoint, DHGTCs and PDTCs may be *BRAF*- or *RAS*-driven lesions, which are due to whether the preceding lesion was a PTC or FTC (Baloch *et al.* 2022). Interestingly, DHGTCs are mostly derived from *BRAF*-driven PTCs, while PDTCs often exhibit aberrant *RAS* signaling, indicating a relationship between FTCs and FVPTCs (Wong *et al.* 2021). In the process of dedifferentiation, additional genetic alterations are usually seen in DHGTCs and PDTCs, including *TERT* promoter and *TP53* gene mutations (Paulsson *et al.* 2020, Baloch *et al.* 2022). In addition, an association with mutations in the micro-RNA master regulator *DICER1* is also noted in some PDTC cases in adolescents (Chernock *et al.* 2020).

Anaplastic thyroid carcinoma

In the fourth edition of the WHO classification, squamous cell carcinoma (SCC) of the thyroid gland was listed as a separate entity from anaplastic thyroid carcinoma (ACA); however, studies have shown both clinically behaved in a similar manner. The molecular profiling has solved this diagnostic conundrum; a vast majority of SCC of the thyroid harbor *BRAF* p.V600E mutations and exhibit TTF1 and PAX8 immunoexpression, proving the follicular cell

https://erc.bioscientifica.com
https://doi.org/10.1530/ERC-22-0293
© 2022 the author(s)
Published by Bioscientifica Ltd.
Printed in Great Britain

Downloaded from Bioscientifica.com at 03/10/2026 12:42:14AM
via free access

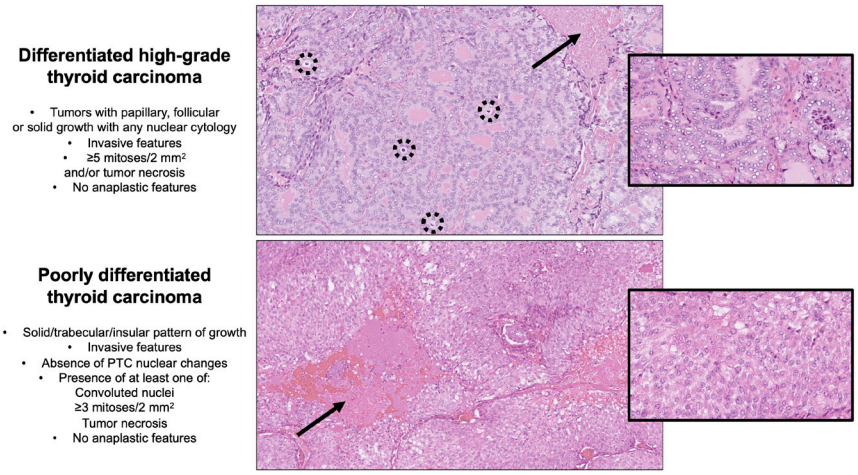

Figure 3
Diagnostic requirements for high-grade follicular cell-derived carcinomas. Introduced for the first time, the entity 'differentiated high-grade thyroid carcinoma' (DHGTC) encompasses follicular cell-derived tumors with well-differentiated histology (papillary or follicular growth, invasion, PTC-related nuclear atypia may be present) but with an elevated mitotic count and/or tumor necrosis. These tumors exhibit an aggressive clinical course comparable to poorly differentiated thyroid carcinoma (PDTC), an entity classified via the so-called Turin criteria, in which the growth pattern is either solid, trabecular or insular. PTC-related atypia must be excluded and either one of convoluted nuclei, an elevated mitotic count or tumor necrosis must be present. In this illustration, a DHGTC is presented in the top row, with dashed circles marking mitoses and a black arrow pointing to tumor necrosis. The insert shows retained PTC nuclear atypia. In the bottom row, a PDTC is depicted with solid growth. Note the lack of PTC-related nuclear changes as well as follicular growth (insert). Tumor necrosis is noted (black arrow).

origin (Lam *et al.* 2001, Xu *et al.* 2020). Moreover, SCCs of the thyroid can be seen in conjunction with well-differentiated thyroid carcinoma, and similarly, a subset of ACAs display easily recognizable squamous differentiation – making it logical to classify SCC of the thyroid as a morphological pattern/subtype of ACA rather than a separate entity (Baloch *et al.* 2022). The new classification also encourages routine use of *BRAF* p.V600E mutation-specific VE1 immunohistochemistry in all patients with ACA given the potential benefit of BRAF and MEK inhibitor therapies (Baloch *et al.* 2022).

Grading of medullary thyroid carcinoma: not a WHO grading but a recommendation for clinical risk assessment

Recently, an international study has recommended two-tiered grading of medullary thyroid carcinoma. This is based on strong association between worse patient outcomes and high-grade pathologic features such as tumor necrosis and an elevated mitotic count or Ki67 proliferation index (Alzumaili *et al.* 2020, Fuchs *et al.* 2020, Asa & Mete 2022, Vissio *et al.* 2022, Williams *et al.* 2022, Xu *et al.* 2022). By using this approach, MTCs are defined as high-grade tumors based upon the presence of at least one of the following parameters: tumor necrosis, mitotic count ≥5 per 2 mm² and/or a Ki67 proliferation index ≥ 5% (Fig. 4). The majority (approximately 75%) of MTCs in this study were low-grade tumors, showing absence of necrosis, few mitotic figures and a low Ki67 index. This grading system was an independent predictor of worse outcome irrespective of TNM stage, *RET* mutational status and various additional clinical parameters and is therefore highlighted in fifth edition of WHO classification of thyroid neoplasms in order to identify patients with higher risks of recurrences and adverse outcome (Xu *et al.* 2022). Of note, this approach requires extensive sampling to avoid missing focal areas with necrosis and the Ki67 index needs to be appreciated in hotspot areas (with the highest proliferative activity) (Baloch *et al.* 2022). Recent evidence also highlights the importance of other clinicopathological variables (Le *et al.* 2022) and tumor histological features (Khandakar *et al.* 2022).

Salivary gland-type neoplasms and intrathyroidal thymic tumors

Intrathyroidal salivary gland-type neoplasms are exceedingly rare neoplasms and include mucoepidermoid carcinoma (MEC) and secretory carcinoma (SC) (Baloch *et al.* 2022). A majority of experts agree that these tumors may originate from ectopic salivary gland elements located in the thyroid pseudo-capsule or within thyroid parenchyma. Both tumors display morphologies similar to their counterparts in the salivary glands, but they also show diverse epidemiologic, molecular and prognostic

https://erc.bioscientifica.com
https://doi.org/10.1530/ERC-22-0293
© 2022 the author(s)
Published by Bioscientifica Ltd.
Printed in Great Britain

Downloaded from Bioscientifica.com at 03/10/2026 12:42:14AM
via free access

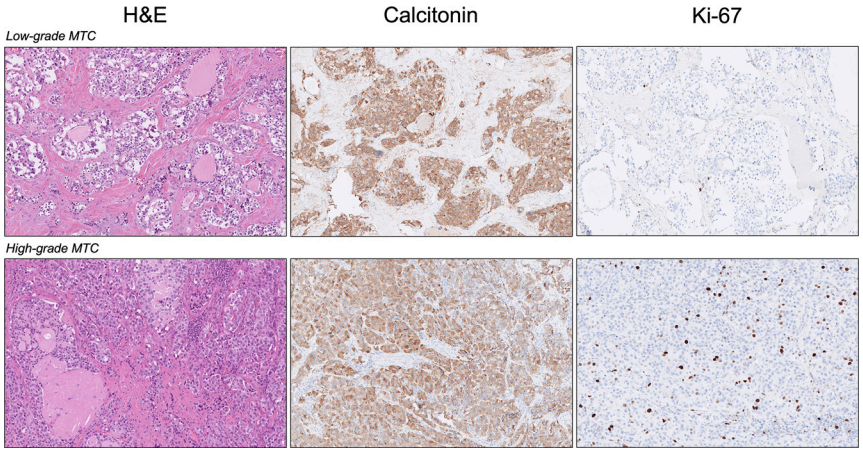

Figure 4
Histological grading of medullary thyroid carcinoma. The 2022 WHO classification endorses grading of medullary thyroid carcinoma (MTC) into high- and low-grade lesions, in which the former entity exhibits tumor necrosis, mitotic count ≥5 per 2 mm² and/or a Ki67 proliferation index ≥5%. Top row: low-grade MTC on hematoxylin and eosin (H&E) stain verified by calcitonin immunohistochemistry, displaying a Ki67 index of <1%. Bottom row: high-grade MTC with a Ki67 index of 10%. This tumor has an unfavorable prognosis compared to its low-grade counterpart.

features that differ from their salivary gland counterparts (Chambers *et al.* 2021).

Thyroid MECs are usually composed of mucinous, intermediate and squamous cells that are arranged in solid and cystic growth, confirmed by positive p63 and CK5 immunostaining. *MAML2* gene rearrangements are not as frequent as in their salivary gland counterparts (Tonon *et al.* 2003) since thyroid MECs have been reported to represent metaplastic follicular cell-derived thyroid carcinomas in some manifestations (Baloch *et al.* 2000, Chambers *et al.* 2021).

The hallmark pathologic features of SC are eosinophilic cells with vacuolated cytoplasm. Similar to SC of salivary gland, they are positive for GATA3, mammaglobin, GCDFP15 and S100 protein, while consistently negative for TTF1 and thyroglobulin (Baloch *et al.* 2022). However, variable PAX8 reactivity can occur (Asa & Mete 2018). To date, all thyroid SCs displayed *ETV6::NTRK3* fusions (Skálová *et al.* 2010). Unlike most salivary gland SCs, thyroid SCs tend to be associated with a more aggressive clinical outcome and have been particularly reported in a later age onset. Interestingly, both MEC and SC have been reported to co-occur with follicular cell-derived thyroid carcinomas.

The intrathyroidal thymic tumors include thymoma and thymic carcinoma families and 'intrathyroidal spindle epithelial tumor with thymus-like elements'. These are classified similar to the fourth edition of WHO classification of thyroid tumors (Baloch *et al.* 2022). The tumor formerly known as 'thyroid carcinoma showing thymic-like differentiation' is now termed as 'intrathyroid thymic carcinoma' (ITC) to lessen the ambiguity regarding origin of this rare malignancy. No diagnostic molecular profile of these lesions is available at this time; ITC may display *TERT* promoter mutations, which are generally absent in mediastinal thymic carcinomas (Tahara *et al.* 2020).

Thyroid tumors of uncertain histogenesis

The 'cribriform-morular variant of papillary thyroid carcinoma' has been renamed to 'cribriform-morular thyroid carcinoma' in the fifth edition of WHO classification of thyroid tumors (Boyraz *et al.* 2021, Baloch *et al.* 2022, Nosé *et al.* 2022). The hallmark of these tumors is the presence of nuclear and cytoplasmic beta-catenin expression. The reasons for this nomenclature change are the following (Boyraz *et al.* 2021): (1) these tumors lack expression of thyroglobulin, are often negative for PAX8 (or can be very focal/weak positive) and only express TTF1 in focal areas with cribriform patterns; (2) aberrant expression of estrogen and progesterone receptors is noted within the cribriform areas, while the morular component expresses CD5, CK5, CDX2 and CD10 proteins, not observed in follicular cell-derived lesions and (3) these lesions are driven by genetic aberrancies in the Wnt pathway, most notably *APC* gene mutations resulting in nuclear localization of beta-catenin. Based on these findings, the definite histogenesis of this lesion is disputable but definitely argues against a follicular cell-derived origin.

On a similar note, the exact origin of the rare entity 'sclerosing mucoepidermoid carcinoma with eosinophilia' is also not known. These tumors lack PAX8 and thyroglobulin expression, although focal/variable TTF1 immunoreactivity may be seen (Baloch *et al.* 2022). Molecular analyses show neither mutations encountered in follicular cell-derived thyroid carcinoma nor gene fusions that are usually observed in the salivary gland counterpart. Due to the p63 positivity, some believe these

https://erc.bioscientifica.com
https://doi.org/10.1530/ERC-22-0293
© 2022 the author(s)
Published by Bioscientifica Ltd.
Printed in Great Britain

Downloaded from Bioscientifica.com at 03/10/2026 12:42:14AM
via free access

lesions derive from solid nest cells (ultimobranchial body remnant cells) or squamous metaplasia, but this needs to be proven by further analysis (Chan *et al.* 1991, Hunt *et al.* 2004, Baloch *et al.* 2022).

Molecular biomarkers: current and future use

In the era of personalized medicine, assessment of the genetic alterations underlying the development of each individual tumor is believed to influence how we classify based on pathologic features, prognosticate and treatment. While virtually all thyroid tumors are diagnosed using histomorphologic features (sometimes accompanied by immunohistochemistry), there will be an increasing need to characterize these lesions from a molecular standpoint, especially for cases that respond poorly to conventional treatment protocols. The development of thyroid cancer is a multistep process involving both early driver changes as well as late event changes. The well-differentiated thyroid carcinomas (PTC and FTC) usually are *BRAF*- or *RAS*-driven (Nikiforov 2004, Cancer Genome Atlas Research Network 2014, Paulsson *et al.* 2020, Baloch *et al.* 2022). *BRAF*-driven events include *BRAF* p.V600E mutations as well as gene fusions involving *ALK*, *BRAF*, *RET*, *NTRK1/3* and *MET*, while RAS-driven lesions exhibit mutations in *N/K/HRAS* mutations, *BRAF* (K601E), *DICER1*, *PTEN* and *PAX8::PPARG* fusions (Baloch *et al.* 2022). If the tumor progresses to either DHGTC, PDTC or ACA, additional genetic events take place, including mutations in the *TERT* promoter, *TP53*, cell cycle genes, chromatin-remodeling genes and mismatch repair genes (Kunstman *et al.* 2015, Pozdeyev *et al.* 2018, Paulsson *et al.* 2020, Stenman *et al.* 2021). In the fifth edition of WHO classification of thyroid tumors, a balanced approach is taken to highlight the potential therapeutic value of detecting *RET* fusions or *BRAF* p.V600E mutations in PTC, as well as *NTRK1/3* and *ALK* fusions in PTC or FTC. Moreover, the need for reflex testing of all ACAs for *BRAF* p.V600E mutations is also emphasized.

Parting thoughts

The present is an exciting time for the field of endocrine pathology (Asa *et al.* 2022). The traditional paradigms for diagnosis and classifying thyroid tumors based purely on morphologic features are now enriched by thorough understanding of management-centric histologic features (low- vs high-grade features), immunohistochemical and molecular characterization. These altogether have led to the diagnostic framework for the 2022 WHO classification of thyroid lesions, which by no means is to be perceived to increase the workload in the everyday practice of thyroid pathology – but rather having pathologists as part of the multidisciplinary team in era of precision medicine. We also believe that this new classification scheme serves as a fertile ground for future iterations which will incorporate more molecular data to provide a robust scheme for classifying thyroid neoplasms.

Declaration of interest
There is no conflict of interest that could be perceived as prejudicing the impartiality of the research reported.

Funding
This work did not receive any specific grant from any funding agency in the public, commercial or not-for-profit sector.

Author contribution statement
Conception and design of the work: OM and ZWB. Drafting the article and figures: CCJ. Critical revision of the article: OM, ZWB.

References

Alzumaili B, Xu B, Spanheimer PM, Tuttle RM, Sherman E, Katabi N, Dogan S, Ganly I, Untch BR & Ghossein RA 2020 Grading of medullary thyroid carcinoma on the basis of tumor necrosis and high mitotic rate is an independent predictor of poor outcome. *Modern Pathology* **33** 1690–1701. (https://doi.org/10.1038/s41379-020-0532-1)

Asa SL, Erickson LA & Mete O 2022 The next steps for endocrine pathology. *Endocrine Pathology* **33** 228–230. (https://doi.org/10.1007/s12022-022-09711-7)

Asa SL & Mete O 2018 An unusual salivary gland tumor mimicking papillary thyroid carcinoma: mammary analog secretory carcinoma. *Frontiers in Endocrinology* **9** 555. (https://doi.org/10.3389/fendo.2018.00555)

Asa SL & Mete O 2022 Medullary thyroid carcinoma in the IARC/WHO neuroendocrine schema. *Endocrine Pathology* **33** 346–347. (https://doi.org/10.1007/s12022-022-09728-y)

Baloch ZW, Asa SL, Barletta JA, Ghossein RA, Juhlin CC, Jung CK, LiVolsi VA, Papotti MG, Sobrinho-Simões M, Tallini G, *et al.* 2022 Overview of the 2022 WHO classification of thyroid neoplasms. *Endocrine Pathology* **33** 27–63. (https://doi.org/10.1007/s12022-022-09707-3)

Baloch ZW, Solomon AC & LiVolsi VA 2000 Primary mucoepidermoid carcinoma and sclerosing mucoepidermoid carcinoma with eosinophilia of the thyroid gland: a report of nine cases. *Modern Pathology* **13** 802–807. (https://doi.org/10.1038/modpathol.3880140)

Boyraz B, Sadow PM, Asa SL, Dias-Santagata D, Nosé V & Mete O 2021 Cribriform-morular thyroid carcinoma is a distinct thyroid malignancy of uncertain cytogenesis. *Endocrine Pathology* **32** 327–335. (https://doi.org/10.1007/s12022-021-09683-0)

© 2022 the author(s)
Published by Bioscientifica Ltd.
Printed in Great Britain

Downloaded from Bioscientifica.com at 03/10/2026 12:42:14AM
via free access

Cameselle-Teijeiro JM, Mete O, Asa SL & LiVolsi V 2021 Inherited follicular epithelial-derived thyroid carcinomas: from molecular biology to histological correlates. *Endocrine Pathology* **32** 77–101. (https://doi.org/10.1007/s12022-020-09661-y)

Cancer Genome Atlas Research Network 2014 Integrated genomic characterization of papillary thyroid carcinoma. *Cell* **159** 676–690. (https://doi.org/10.1016/j.cell.2014.09.050)

Caturegli P & Ruggere C 2005 Karl Hürthle! Now, who was he? *Thyroid* **15** 121–123. (https://doi.org/10.1089/thy.2005.15.121)

Chambers M, Nosé V, Sadow PM, Tafe LJ & Kerr DA 2021 Salivary-like tumors of the thyroid: a comprehensive review of three rare carcinomas. *Head and Neck Pathology* **15** 212–224. (https://doi.org/10.1007/s12105-020-01193-5)

Chan JK, Albores-Saavedra J, Battifora H, Carcangiu ML & Rosai J 1991 Sclerosing mucoepidermoid thyroid carcinoma with eosinophilia. A distinctive low-grade malignancy arising from the metaplastic follicles of Hashimoto's thyroiditis. *American Journal of Surgical Pathology* **15** 438–448. (https://doi.org/10.1097/00000478-199105000-00003)

Chernock RD, Rivera B, Borrelli N, Hill DA, Fahiminiya S, Shah T, Chong AS, Aqil B, Mehrad M, Giordano TJ, *et al.* 2020 Poorly differentiated thyroid carcinoma of childhood and adolescence: a distinct entity characterized by DICER1 mutations. *Modern Pathology* **33** 1264–1274. (https://doi.org/10.1038/s41379-020-0458-7)

Derwahl M & Studer H 2002 Hyperplasia versus adenoma in endocrine tissues: are they different? *Trends in Endocrinology and Metabolism* **13** 23–28. (https://doi.org/10.1016/s1043-2760(01)00519-7)

Doerfler WR, Nikitski AV, Morariu EM, Ohori NP, Chiosea SI, Landau MS, Nikiforova MN, Nikiforov YE, Yip L & Manroa P 2021 Molecular alterations in Hürthle cell nodules and preoperative cancer risk. *Endocrine-Related Cancer* **28** 301–309. (https://doi.org/10.1530/ERC-20-0435)

Fuchs TL, Nassour AJ, Glover A, Sywak MS, Sidhu SB, Delbridge LW, Clifton-Bligh RJ, Gild ML, Tsang V, Robinson BG, *et al.* 2020 A proposed grading scheme for medullary thyroid carcinoma based on proliferative activity (Ki-67 and mitotic count) and coagulative necrosis. *American Journal of Surgical Pathology* **44** 1419–1428. (https://doi.org/10.1097/PAS.0000000000001505)

Gnemmi V, Renaud F, Do Cao C, Salleron J, Lion G, Wemeau JL, Copin MC, Carnaille B, Leteurtre E, Pattou F, *et al.* 2014 Poorly differentiated thyroid carcinomas: application of the Turin proposal provides prognostic results similar to those from the assessment of high-grade features. *Histopathology* **64** 263–273. (https://doi.org/10.1111/his.12246)

Gopal RK, Kübler K, Calvo SE, Polak P, Livitz D, Rosebrock D, Sadow PM, Campbell B, Donovan SE, Amin S, *et al.* 2018 Widespread chromosomal losses and mitochondrial DNA alterations as genetic drivers in Hürthle cell carcinoma. *Cancer Cell* **34** 242–255.e5. (https://doi.org/10.1016/j.ccell.2018.06.013)

Gozu HI, Lublinghoff J, Bircan R & Paschke R 2010 Genetics and phenomics of inherited and sporadic non-autoimmune hyperthyroidism. *Molecular and Cellular Endocrinology* **322** 125–134. (https://doi.org/10.1016/j.mce.2010.02.001)

Harrer P, Bröcker M, Zint A, Derwahl M, Barbera L & Zumtobel V 1998*a* The clonality of nodules in recurrent goiters at second surgery. *Langenbeck's Archives of Surgery* **383** 453–455. (https://doi.org/10.1007/s004230050159)

Harrer P, Broecker M, Zint A, Schatz H, Zumtobel V & Derwahl M 1998*b* Thyroid nodules in recurrent multinodular goiters are predominantly polyclonal. *Journal of Endocrinological Investigation* **21** 380–385. (https://doi.org/10.1007/BF03350774)

Hiltzik D, Carlson DL, Tuttle RM, Chuai S, Ishill N, Shaha A, Shah JP, Singh B & Ghossein RA 2006 Poorly differentiated thyroid carcinomas defined on the basis of mitosis and necrosis: a clinicopathologic study of 58 patients. *Cancer* **106** 1286–1295. (https://doi.org/10.1002/cncr.21739)

Hodak S, Tuttle RM, Maytal G, Nikiforov YE & Randolph G 2016 Changing the cancer diagnosis: the case of follicular variant of papillary thyroid cancer-primum non nocere and NIFTP. *Thyroid* **26** 869–871. (https://doi.org/10.1089/thy.2016.0205)

Hunt JL, LiVolsi VA & Barnes EL 2004 p63 expression in sclerosing mucoepidermoid carcinomas with eosinophilia arising in the thyroid. *Modern Pathology* **17** 526–529. (https://doi.org/10.1038/modpathol.3800021)

Juhlin CC, Stenman A & Zedenius J 2021 Macrofollicular variant follicular thyroid tumors are DICER1 mutated and exhibit distinct histological features. *Histopathology* **79** 661–666. (https://doi.org/10.1111/his.14416)

Kamilaris CDC, Faucz FR, Voutetakis A & Stratakis CA 2019 Carney complex. *Experimental and Clinical Endocrinology & Diabetes* **127** 156–164. (https://doi.org/10.1055/a-0753-4943)

Kebebew E, Weng J, Bauer J, Ranvier G, Clark OH, Duh QY, Shibru D, Bastian B & Griffin A 2007 The prevalence and prognostic value of BRAF mutation in thyroid cancer. *Annals of Surgery* **246** 466–471. (https://doi.org/10.1097/SLA.0b013e318148563d)

Khandakar H, Agarwal S, Sharma MC, Kandasamy D, Bal C, Rathode Y & Aphale R 2022 Amphicrine medullary thyroid carcinoma - a case-based review expanding on its MUC expression profile. *Endocrine Pathology* **33** 378–387. (https://doi.org/10.1007/s12022-022-09725-1)

Kunstman JW, Juhlin CC, Goh G, Brown TC, Stenman A, Healy JM, Rubinstein JC, Choi M, Kiss N, Nelson-Williams C, *et al.* 2015 Characterization of the mutational landscape of anaplastic thyroid cancer via whole-exome sequencing. *Human Molecular Genetics* **24** 2318–2329. (https://doi.org/10.1093/hmg/ddu749)

Lam KY, Lo CY & Liu MC 2001 Primary squamous cell carcinoma of the thyroid gland: an entity with aggressive clinical behaviour and distinctive cytokeratin expression profiles. *Histopathology* **39** 279–286. (https://doi.org/10.1046/j.1365-2559.2001.01207.x)

Le MK, Kawai M, Odate T, Vuong HG, Oishi N & Kondo T 2022 Metastatic risk stratification of 2526 medullary thyroid carcinoma patients: a study based on surveillance, epidemiology, and end results database. *Endocrine Pathology* **33** 348–358. (https://doi.org/10.1007/s12022-022-09724-2)

Leonardo E, Volante M, Barbareschi M, Cavazza A, Dei Tos AP, Bussolati G & Papotti M 2007 Cell membrane reactivity of MIB-1 antibody to Ki67 in human tumors: fact or artifact? *Applied Immunohistochemistry and Molecular Morphology* **15** 220–223. (https://doi.org/10.1097/01.pai.0000213122.66096.f0)

Lukovic J, Petrovic I, Liu Z, Armstrong SM, Brierley JD, Tsang R, Pasternak JD, Gomez-Hernandez K, Liu A, Asa SL, *et al.* 2021 Oncocytic papillary thyroid carcinoma and oncocytic poorly differentiated thyroid carcinoma: clinical features, uptake, and response to radioactive iodine therapy, and outcome. *Frontiers in Endocrinology* **12** 795184. (https://doi.org/10.3389/fendo.2021.795184)

McFadden DG & Sadow PM 2021 Genetics, diagnosis, and management of Hürthle cell thyroid neoplasms. *Frontiers in Endocrinology* **12** 696386. (https://doi.org/10.3389/fendo.2021.696386)

Mete O & Asa SL 2012 Pitfalls in the diagnosis of follicular epithelial proliferations of the thyroid. *Advances in Anatomic Pathology* **19** 363–373. (https://doi.org/10.1097/PAP.0b013e318271a5ac)

Nikiforov YE 2004 Genetic alterations involved in the transition from well-differentiated to poorly differentiated and anaplastic thyroid carcinomas. *Endocrine Pathology* **15** 319–327. (https://doi.org/10.1385/ep:15:4:319)

Nikiforova MN, Nikitski AV, Panebianco F, Kaya C, Yip L, Williams M, Chiosea SI, Seethala RR, Roy S, Condello V, *et al.* 2019 GLIS rearrangement is a genomic hallmark of hyalinizing trabecular tumor of the thyroid gland. *Thyroid* **29** 161–173. (https://doi.org/10.1089/thy.2018.0791)

Nosé V, Gill A, Teijeiro JMC, Perren A & Erickson L 2022 Overview of the 2022 WHO classification of familial endocrine tumor syndromes. *Endocrine Pathology* **33** 197–227. (https://doi.org/10.1007/s12022-022-09705-5)

Parma J, Duprez L, Van Sande J, Cochaux P, Gervy C, Mockel J, Dumont J & Vassart G 1993 Somatic mutations in the thyrotropin receptor gene

© 2022 the author(s)
Published by Bioscientifica Ltd.
Printed in Great Britain

Downloaded from Bioscientifica.com at 03/10/2026 12:42:14AM
via free access

cause hyperfunctioning thyroid adenomas. *Nature* **365** 649–651. (https://doi.org/10.1038/365649a0)

Paulsson JO, Backman S, Wang N, Stenman A, Crona J, Thutkawkorapin J, Ghaderi M, Tham E, Stålberg P, Zedenius J, *et al.* 2020 Whole-genome sequencing of synchronous thyroid carcinomas identifies aberrant DNA repair in thyroid cancer dedifferentiation. *Journal of Pathology* **250** 183–194. (https://doi.org/10.1002/path.5359)

Pozdeyev N, Gay LM, Sokol ES, Hartmaier R, Deaver KE, Davis S, French JD, Borre PV, LaBarbera DV, Tan AC, *et al.* 2018 Genetic analysis of 779 advanced differentiated and anaplastic thyroid cancers. *Clinical Cancer Research* **24** 3059–3068. (https://doi.org/10.1158/1078-0432.CCR-18-0373)

Skálová A, Vanecek T, Sima R, Laco J, Weinreb I, Perez-Ordonez B, Starek I, Geierova M, Simpson RHW, Passador-Santos F, *et al.* 2010 Mammary analogue secretory carcinoma of salivary glands, containing the ETV6-NTRK3 fusion gene: a hitherto undescribed salivary gland tumor entity. *American Journal of Surgical Pathology* **34** 599–608. (https://doi.org/10.1097/PAS.0b013e3181d9efcc)

Stenman A, Yang M, Paulsson JO, Zedenius J, Paulsson K & Juhlin CC 2021 Pan-genomic sequencing reveals actionable CDKN2A/2B deletions and kataegis in anaplastic thyroid carcinoma. *Cancers* **13** 6340. (https://doi.org/10.3390/cancers13246340)

Tahara I, Oishi N, Mochizuki K, Oyama T, Miyata K, Miyauchi A, Hirokawa M, Katoh R & Kondo T 2020 Identification of recurrent tert promoter mutations in intrathyroid thymic carcinomas. *Endocrine Pathology* **31** 274–282. (https://doi.org/10.1007/s12022-020-09635-0)

Thompson LD 2016 Ninety-four cases of encapsulated follicular variant of papillary thyroid carcinoma: a name change to Noninvasive Follicular thyroid neoplasm with Papillary-like Nuclear Features would help prevent overtreatment. *Modern Pathology* **29** 698–707. (https://doi.org/10.1038/modpathol.2016.65)

Tonon G, Modi S, Wu L, Kubo A, Coxon AB, Komiya T, O'Neil K, Stover K, El-Naggar A, Griffin JD, *et al.* 2003 t(11;19)(q21;p13) translocation in mucoepidermoid carcinoma creates a novel fusion product that disrupts a Notch signaling pathway. *Nature Genetics* **33** 208–213. (https://doi.org/10.1038/ng1083)

Vissio E, Maletta F, Fissore J, Osella Abate S, Retta F, Brizzi MP, Piovesan A, Rossetto Giaccherino R, Volante M & Papotti M 2022 External validation of three available grading systems for medullary thyroid carcinoma in a single institution cohort. *Endocrine Pathology* **33** 359–370. (https://doi.org/10.1007/s12022-022-09719-z)

Volante M, Collini P, Nikiforov YE, Sakamoto A, Kakudo K, Katoh R, Lloyd RV, LiVolsi VA, Papotti M, Sobrinho-Simoes M, *et al.* 2007 Poorly differentiated thyroid carcinoma: the Turin proposal for the use of uniform diagnostic criteria and an algorithmic diagnostic approach. *American Journal of Surgical Pathology* **31** 1256–1264. (https://doi.org/10.1097/PAS.0b013e3180309e6a)

Wasserman JD, Sabbaghian N, Fahiminiya S, Chami R, Mete O, Acker M, Wu MK, Shlien A, de Kock L & Foulkes WD 2018 DICER1 mutations are frequent in adolescent-onset papillary thyroid carcinoma. *Journal of Clinical Endocrinology and Metabolism* **103** 2009–2015. (https://doi.org/10.1210/jc.2017-02698)

Williams JF, Zhao M, Najdawi F, Ahmadi S, Hornick JL, Wong KS & Barletta JA 2022 Grading of medullary thyroid carcinoma: an interobserver reproducibility study. *Endocrine Pathology* **33** 371–377. (https://doi.org/10.1007/s12022-022-09718-0)

Wong KS, Dong F, Telatar M, Lorch JH, Alexander EK, Marqusee E, Cho NL, Nehs MA, Doherty GM, Afkhami M, *et al.* 2021 Papillary thyroid carcinoma with high-grade features versus poorly differentiated thyroid carcinoma: an analysis of clinicopathologic and molecular features and outcome. *Thyroid* **31** 933–940. (https://doi.org/10.1089/thy.2020.0668)

Xu B, Fuchs T, Dogan S, Landa I, Katabi N, Fagin JA, Tuttle RM, Sherman E, Gill AJ & Ghossein R 2020 Dissecting anaplastic thyroid carcinoma: a comprehensive clinical, histologic, immunophenotypic, and molecular study of 360 cases. *Thyroid* **30** 1505–1517. (https://doi.org/10.1089/thy.2020.0086)

Xu B, Fuchs TL, Ahmadi S, Alghamdi M, Alzumaili B, Bani MA, Baudin E, Chou A, De Leo A, Fagin JA, *et al.* 2022 International medullary thyroid carcinoma grading system: a validated grading system for medullary thyroid carcinoma. *Journal of Clinical Oncology* **40** 96–104. (https://doi.org/10.1200/JCO.21.01329)

Xu B, Wang L, Tuttle RM, Ganly I & Ghossein R 2015 Prognostic impact of extent of vascular invasion in low-grade encapsulated follicular cell-derived thyroid carcinomas: a clinicopathologic study of 276 cases. *Human Pathology* **46** 1789–1798. (https://doi.org/10.1016/j.humpath.2015.08.015)

Received in final form 29 September 2022
Accepted 23 November 2022
Accepted Manuscript published online 24 November 2022

© 2022 the author(s)
Published by Bioscientifica Ltd.
Printed in Great Britain

Downloaded from Bioscientifica.com at 03/10/2026 12:42:14AM
via free access